Dr. Robert J. Melillo
119 N Park Ave, Suite 101,
Rockville Centre, New York 11570
+1 (480) 926-1115

DR. ROBERT MELILLO.

QEEG REPORT

Patient:
Name: Isaac Lobato Franca
DOB: 11/06/2018
Age: 6 years old, Male
Right Hemisphere Deficit
qEEG Recorded On: 07/14/2025

History (07/14/2025):

- **Language/Communication:** Currently beginning to use some sentences but often prefers single-word requests. Echolalia and scripting are present. He uses leading and hand-over-hand gestures instead of pointing. Never responded to his name during infancy. No words at age 1.
- **Sleep:** Has had insomnia since age 2; difficulty returning to sleep once awake.
- **Behavioral Features:** Stereotypies include stimming (running back and forth), spinning, hitting walls, gazing sideways, swinging ribbons, opening/closing doors, playing with water, and hanging upside down on couch. Displays high pain threshold, reduced sensitivity to cold/hot.
- **Medical/Gastrointestinal:** Chronic gut issues; intermittent antifungal treatments with limited effect. Food elimination attempted (100% dairy-free, partial reduction of other foods). Antibody testing performed at ~3 years old.

Dr. Robert J. Melillo
119 N Park Ave, Suite 101,
Rockville Centre, New York 11570
+1 (480) 926-1115

DR. ROBERT MELILLO®

qEEG Description

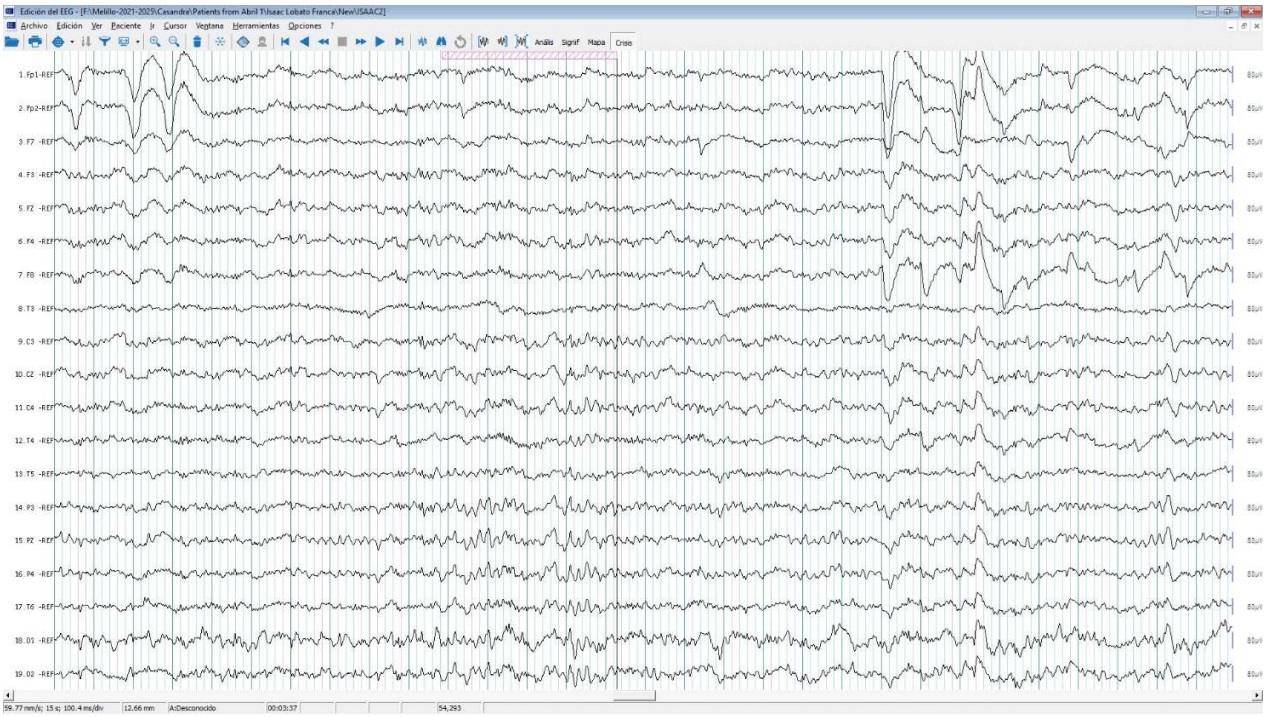

Background Activity

- The tracing shows a disorganized background, lacking a clearly sustained posterior dominant rhythm.
- Mixed-frequency activity is present, with predominance of irregular theta and delta activity diffusely across channels.
- Faster frequencies (beta) are poorly represented and fragmented, with no well-modulated alpha rhythm visible.
- General appearance suggests immature or diffusely slowed cortical organization for age.

Paroxysmal Activity

- Superimposed on the disorganized background, there are paroxysmal discharges consisting of sharp transients and spike–wave bursts.
- These appear multifocal and bilateral, with a tendency to cluster in central and temporal regions.
- Some bursts generalize and disrupt the background organization, consistent with an epileptiform pattern.

Dr. Robert J. Melillo
119 N Park Ave, Suite 101,
Rockville Centre, New York 11570
+1 (480) 926-1115

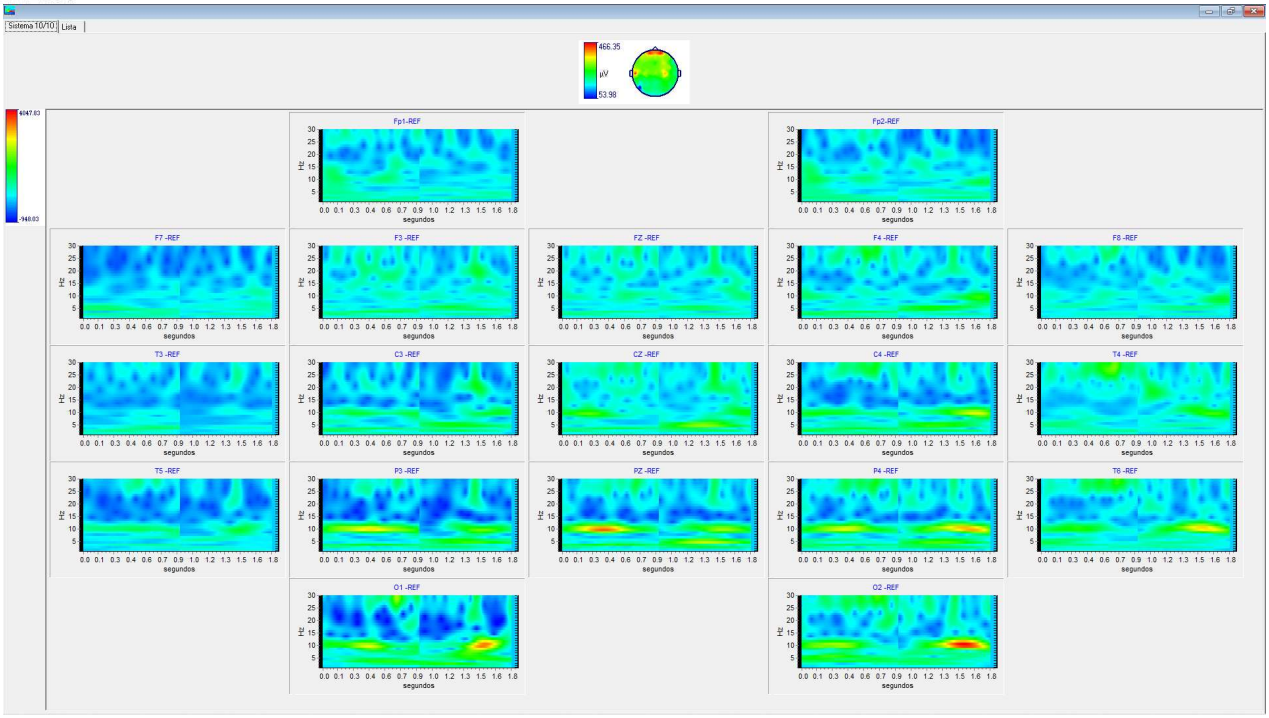

Time-Frequency Analysis

1. **Amplitude of Paroxysms**
   - The color scale indicates paroxysmal activity reaching amplitudes up to ~600 µV.
   - The bursts are strongest in posterior and temporal regions (notably Pz, P3, T6, O1, O2).
   - Compared to background, the paroxysmal events represent clearly higher power, standing out as red/yellow bands in the TF plots.

---

2. **Frequency Content**
   - The paroxysms involve low-to-mid frequency ranges:
     - Delta–theta (2–7 Hz): Most prominent, especially in posterior leads (O1, O2, Pz).
     - Alpha (8–12 Hz): Some involvement, though less intense.
     - Beta (>15 Hz): Minimal, with little extension into higher frequencies.
   - This indicates that the paroxysms are mainly slow-frequency epileptiform bursts, rather than fast-spike discharges.

---

3. **Spatial Distribution**
   - The activity is not generalized, but instead multifocal with posterior predominance.

Dr. Robert J. Melillo
119 N Park Ave, Suite 101,
Rockville Centre, New York 11570
+1 (480) 926-1115

DR. ROBERT MELILLO

- **Strongest involvement: occipital (O1, O2), parietal (Pz, P3, P4), temporal (T6) regions.**
- **Frontal leads show much weaker activation, confirming posterior–temporal dominance of the discharges.**

---

4. Temporal Evolution

- **The bursts last approximately 0.3–0.6 seconds, with abrupt onset and offset.**
- **They appear as short, high-power events, disrupting background organization.**
- **Between paroxysms, power returns to a more diffuse, lower-intensity pattern.**

✅ **Summary**

The time–frequency analysis demonstrates paroxysmal bursts of increased power, predominantly in the 2–7 Hz (delta–theta) range, with maximal expression in posterior and temporal regions (Pz, O1, O2, T6). The discharges are moderate to high amplitude (~600 μV), multifocal, and short-lasting, disrupting background activity but without the diffuse spread seen in more generalized epileptiform discharges.

✅ **Final Summary:**

The EEG background is poorly organized with generalized slowing, dominated by theta–delta activity, and shows superimposed multifocal paroxysmal discharges, some with secondary generalization. This indicates both diffuse cerebral dysfunction and epileptiform instability.

CALIXTO MACHADO, MD, PhD, FAAN
Full Professor and Researcher of Neurology
Corresponding Fellow of the American Academy of Neurology